

Transplant of autologous bone marrow stem cells in ischemic heart disease

Isham Jaafar^{1,6}, Reiji Hattori¹, Azhari Yakub¹, Jeswant Dillon¹, Hassan Ariff², Rosli Ali³,
Kian Meng Chang⁴, Roshida Hassan⁵

¹Department of Cardiothoracic Surgery, National Heart Institute, Kuala Lumpur, Malaysia; ² Department of Anesthesia, National heart Institute, Kuala Lumpur, Malaysia; ³ Department of Cardiology, National Heart Institute, Kuala Lumpur, Malaysia; ⁴ Department of Hematology, Kuala Lumpur General Hospital, Malaysia; ⁵ Department of Pathology, Kuala Lumpur General Hospital, Malaysia; ⁶ Department of General Surgery, RIPAS Hospital, Brunei.

Abstract

The objective of this study was to evaluate the feasibility of intramyocardial injections of autologous bone marrow stem cells as sole therapy for patients with ischemic heart disease. The methods involved a prospective, non randomized study in 4 symptomatic patients who had severe ischemic heart disease, which was not amenable for conventional revascularisation methods. Aspirates of 500ml bone marrow were extracted from the iliac crests. A mean of 2.4×10^8 autologous bone marrow stem cells were delivered to the patients by direct intramyocardial injections at 30-40 sites as predetermined by the preoperative technetium scan. There was no mortality at mean follow-up of 14.3 months (range from 10 to 22 months). The New York Heart Association (NYHA) functional classification improved from a mean of 3.2 preoperatively to a mean of 1.5 and 1.0 at 1- and 4-month follow-up, respectively. The ejection fraction from two-dimensional echocardiography changed from $51 \pm 7\%$ to $62 \pm 4\%$ and the percentage of myocardial defect altered from $73 \pm 23\%$ to $23 \pm 41\%$ at 4-month follow up. Periodic holter monitoring showed no early or late arrhythmias.

Direct delivery of high numbers of autologous bone marrow cells via intramyocardial injections in severely ischaemic patients is feasible and not associated with death, myocardial infarction or cerebrovascular incidents. One year following this intervention qualitative measures suggested improvements in the patients' cardiac function and reduction in their associated cardiac symptoms. A longer follow up is necessary to establish the long-term efficacy of this approach and to investigate whether there are any late arrhythmias.

Introduction

Coronary artery disease remains one of the main causes of morbidity and mortality in the world. Despite advances in medical treatment and improvements in revascularisation techniques, thousands of patients are still not amenable to these treatments thus denying them a symptom-free life. For the past few decades researchers have been attempting to develop and utilise cellular therapy to rebuild or revascularise the heart [1-3]. Early clinical trials have shown that implantation of autologous bone marrow cells

was feasible with improvement in ischaemic status and left ventricular function [4-11]. Indeed this technique has the potential to become one of the emerging new modalities for treatment of ischemic heart disease. However, most of the previous studies with autologous bone marrow stem cells were performed with concomitant percutaneous coronary intervention (PCI) or coronary artery bypass graft surgery (CABG). In this report we describe our preliminary clinical trials and report our result on the safety and feasibility of direct intramyocardial injections using high cell count of autologous bone marrow stem cells as a sole therapy for severe ischaemic heart disease.

Methods

This was a prospective non-randomized clinical trial. All patients who had severe ischemic heart disease with stable angina that was refractory to maximum medical therapy and not amenable for percutaneous or surgical

Corresponding author:

Isham Jaafar

Department of General Surgery, RIPAS Hospital,
Bandar Seri Begawan, Brunei Darussalam

Tel: +63- 2242424

E mail: ishjaafar@hotmail.com

revascularization methods either because of diffuse disease or the target vessels were too small, were eligible for recruitment. This has to be validated by an independent interventional cardiologist and cardiothoracic surgeon. Additional inclusion criteria include the presence of myocardial reversibility as confirmed by preoperative technetium scan. This study was approved by the institutional ethical committee and informed consent was obtained from all the patients. Exclusion criteria included: life expectancy of less than a year, active malignant neoplasm, alcohol or drug dependency, severe diabetic retinopathy, poorly controlled diabetes and those requiring concomitant open-heart procedures. Since September 2003, four patients were enrolled.

Preoperative screening

All patients had a repeat coronary angiogram within a month of the procedure to ensure that the coronary arteries were not suitable for percutaneous coronary intervention or surgical revascularization and this was assessed by an independent interventional cardiologist and cardiothoracic surgeon. During cardiac catheterization, left ventriculogram was performed to measure the left ventricular ejection fraction (LVEF), left ventricular end-diastolic pressure (LVEDP), left ventricular end-systolic volume (LVESV) and left ventricular end-diastolic volume (LVEDV) were measured. A SPECT (single photon emission computed tomography) myocardial perfusion-imaging scan using Gamma camera (GE model Optima nx dual detector) was used to detect areas of defect or reversibility. A one day stress-rest or rest-stress protocol was performed. Exercise treadmill (Bruce's protocol) or intravenous dobutamine infusion was aimed at achieving a target heart rate of more than 85%. Then 10-15 mCi of technetium (^{99m}Tc -tetrofosmin) was injected. After about half-hour later, images were acquired over 15 minutes (stress scan). About 3 to 4 hours later another 25 to 30 mCi of technetium scan was injected again. Patient was rested for 45 minutes to one hour before a second scan was acquired (rest scan). Data was collected in optical disc with Dicom compatible format with HP (Hewlett Packard) Kayak as workstation computer. The

areas of defect and reversibility were calculated by Cedar Sinai software. Transthoracic two-dimensional echocardiography was also used to assess the global LVEF, regional wall motions and absence of valvular abnormalities. A preoperative 24-hour holter was also used to exclude presence of any arrhythmia. A detailed computed tomography of the abdomen complimented with abdominal ultrasound, chest roentogram, faecal occult blood test, urinary analysis and serum tumor markers such as carcinoembryonic antigen (CEA) CA19-9 and alpha feto protein (AFP) were done to exclude the presence of malignancy. Eye assessment was done by independent ophthalmologist to exclude presence of severe diabetic retinopathy. Blood sugar monitoring in particular glycosylated hemoglobin and fasting blood sugar were optimized prior to the procedure.

Bone Marrow Aspiration

This was done on the same day of the intramyocardial injection. Patients were anaesthetized with full intubations and placed in prone position. The patient was heparinised with monoparin (heparin sodium bovine, CP Pharmaceuticals) 70 iu/kg body weight just prior to the commencement of the bone marrow harvest. The marrow was aspirated using Islamic needle from both the posterior superior iliac crests. Aliquots of 3-5 mls were aspirated each time. The marrow was then deposited into ACD (acid-citrate-dextrose) and heparinised collection bag. At the start of the harvest, 20mls of ACD and 20mls of hepsal (hepsal = 15,000 iu of preservative-free heparin in 500mls of normal saline) were added into the empty collection bag (Fenwal Bone marrow Collection Kit, Baxter Healthcare Corporation). This combination was sufficient to anticoagulate 100mls of bone marrow. After each 100mls of bone marrow collection, an additional of 20mls of ACD and 15mls of hepsal were added. A total of 500mls of marrow was collected from each patient.

Isolation of Autologous Bone Marrow Stem Cells

Following harvest of about 500mls of the marrow, the collection was sent to the pathology laboratory. A buffy coat was prepared using semi-automated cell

processor Cobe 2991. At the end of the process, the volume is reduced to about 250ml. This procedure depleted the red cells and also reduced the volume. This is later centrifuged at 4000rpm for 20 minutes at 18 degrees celsius without braking. From this about 15ml of concentrated buffy coat was then collected using an automated collection system called 'Optipress' into a transfer bag and ready for injection. Tests on the final harvest included flow cytometry (CD34, B and T-cells subset enumeration) and culture and sensitivity to check for sterility.

Cell implantation

The patients either had a median sternotomy or lateral thoracotomy depending on areas to be injected. Direct intramyocardial injection of high cell count of autologous bone marrow stem cell was done under general anaesthesia and with the heart beating without the aid of cardiopulmonary bypass. A total of 30-40 injections with a mean number of 2.4×10^8 cells (ranges from 1.1×10^8 to 4.2×10^8) injected directly under vision into the myocardium as determined preoperatively from the preoperative technetium scan (Table 1). The injections were spaced at about 0.5cm

Patient	Sex	Age	DM	HPT	HLP	Previous CABG	Total injections	Total cells ($\times 10^9$)
1	male	60	yes	yes	yes	yes	40	1.1
2	male	59	yes	yes	yes	yes	40	2.8
3	male	60	yes	yes	yes	no	31	4.2
4	male	58	yes	yes	yes	yes	33	1.3

Dm=Diabetes mellitus, HPT=Hypertensive, HLP=Hyperlipidemia, CABG=coronary artery bypass garft

Table1. Patient clinical characteristics and intraoperative data

from each other using 27 gauge needle. There were no complications during the injections and in particular no significant arrhythmias or bleeding were noted. No patients required conversion to cardiopulmonary bypass support or intra aortic balloon pump postoperatively. The chest was closed in the routine manner. There were no special requirements postoperatively apart from

low dose of intravenous nitroglycerine for the first 24 hours. All preoperative medications were restarted on the following postoperative day. The patients had repeated invasive and non-invasive assessments or investigations at 1 month, 4 month and 12-month postoperative period. This included coronary angiogram with left ventriculography, SPECT scan, 2-Dimensional echocardiography, 24-hour holter and tumour markers.

Statistics

Results are reported as the mean value \pm standard deviation. Comparison of the changes from baseline to 12 months in these patients was assessed with Friedman test. A probability value <0.05 was considered statistically significant. Statistical analysis was done with SPSS version 12.0 for windows.

Results

All four patients enrolled were male. The median age was 59.3 years (range from 58 to 60 years old). The bone marrow aspiration went uneventfully and the intramyocardial implantation was completed successfully without any complication. Two patients had resternotomies for previous coronary artery bypass graft surgery, one had lateral thoracotomy and one other median sternotomy. Transesophageal echocardiography was used routinely during the intramyocardial injections to exclude accidental systemic embolisation, in which there was none. The patients were restarted on their preoperative medication but antianginal medication was withdrawn at 1 month follow-up. All except one patient completed the 12-month assessment postoperatively. There was no death, myocardial infarctions or cerebrovascular accidents during the procedure or at our follow up median of 14.3 months (ranges from 10 to 22 months). Periodic holter study showed no arrhythmias. Patients' symptoms improved as early as 1 month postoperatively and continued to do so at their last follow up. The New York Heart Association (NYHA) functional class improved from a mean of 3.2 preoperatively to a mean of 1.5 and 1.0 at 1 and

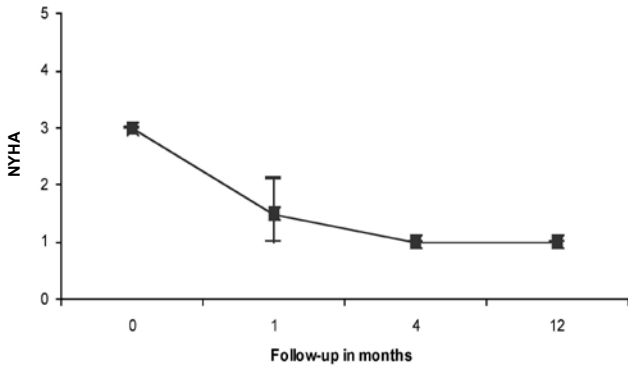


Figure 1. The NYHA functional classification from preoperative to postoperative period at follow up (p=0.041)

4 month follow up (Figure 1). This showed statistical significance with p=0.041. The Canadian Classification Score (CCS) for angina also showed a statistically significant change (p=0.049) with improvement from 2.3 preoperatively to 0 at 4 month postoperatively (Figure 2). The two dimensional echocardiography

R & D and Human Development

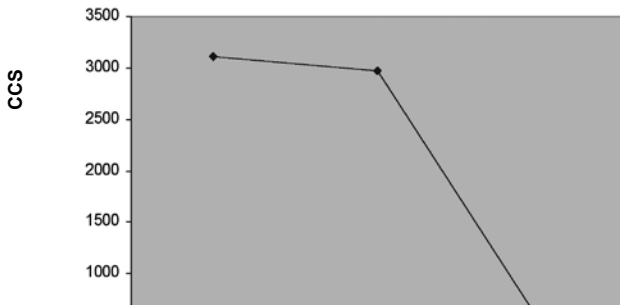
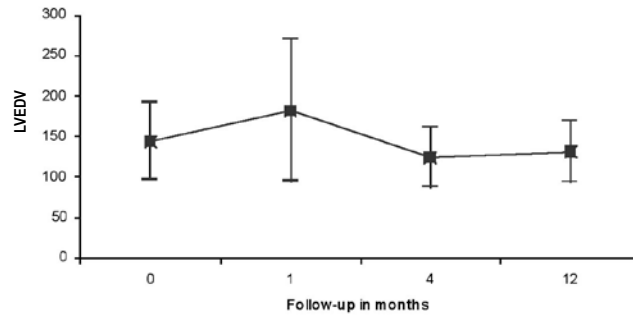
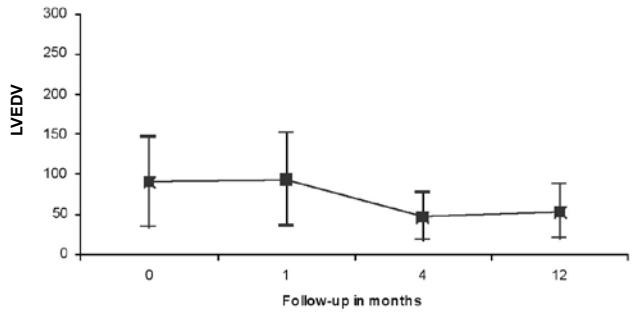


Figure 2. The CCS scoring at preoperative and postoperative follow up (p=0.049)

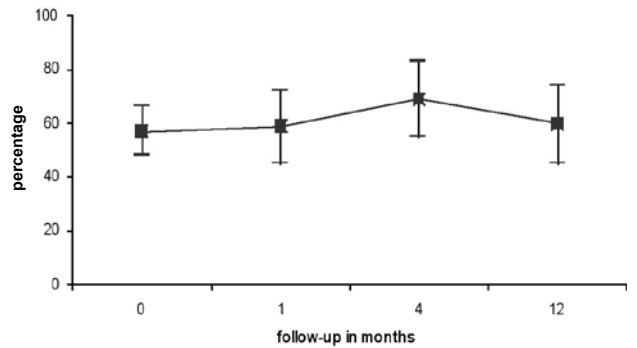
revealed an upward trend in left ventricular ejection fraction from 50±9% preoperatively to 58±14% at 12 months (p=0.117). Results from LV angiography (LVEF, LVESV and LVEDV) at baseline and at 1, 4 and 12-month follow up showed improvement but statistical significance was not reached (Figure 3). The areas of defect and reversibility from the technetium scan illustrated improvement but again did not show statistical significance (Figure 4). Most importantly all the patients managed to be independent and able to go back to work.



a. Left ventricular end-diastolic volume (LVEDV), p=0.457

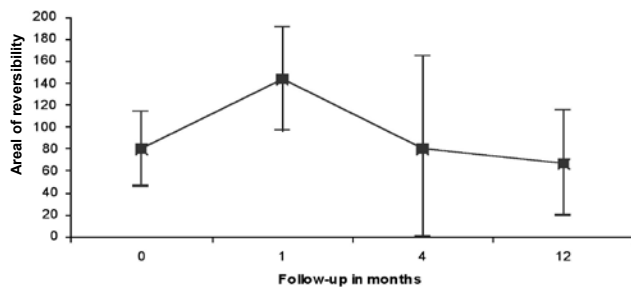


b. Left ventricular end-systolic volume (LVESV), p=0.199

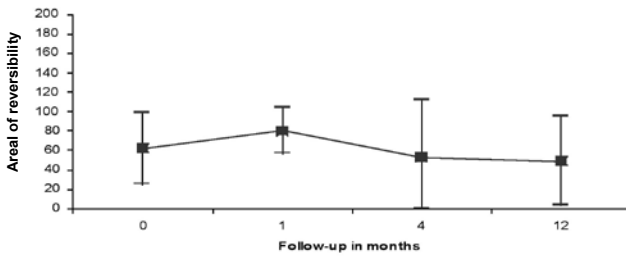


c. Left ventricular ejection fraction (LVEF), p=0.444

Figure 3. Left ventriculography at preoperative and at follow up

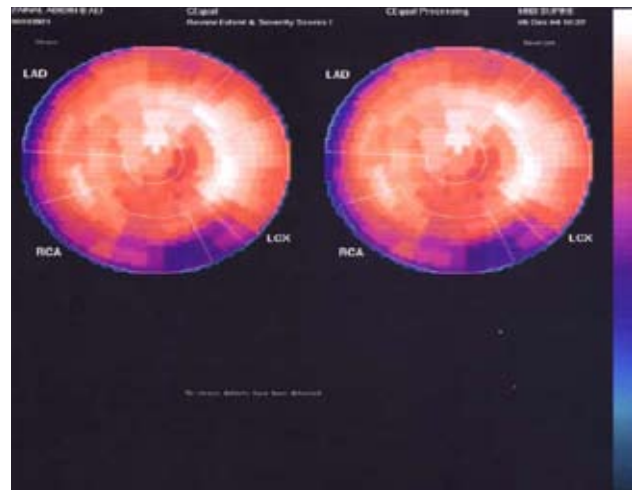


a. Areas of defect (p=0.334)

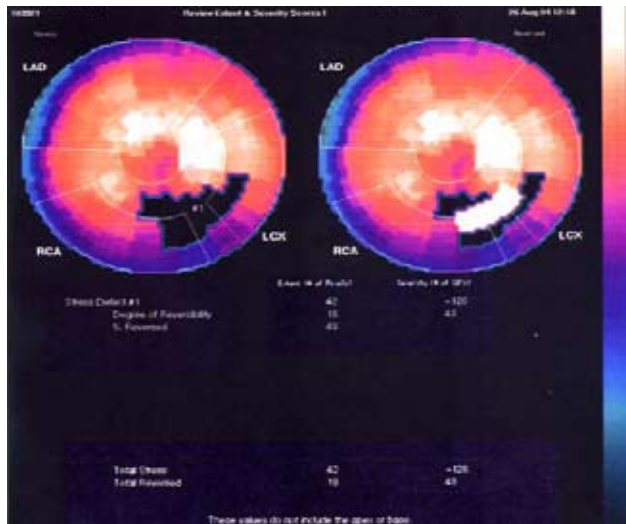


b. Areas of reversibility (p=0.615)

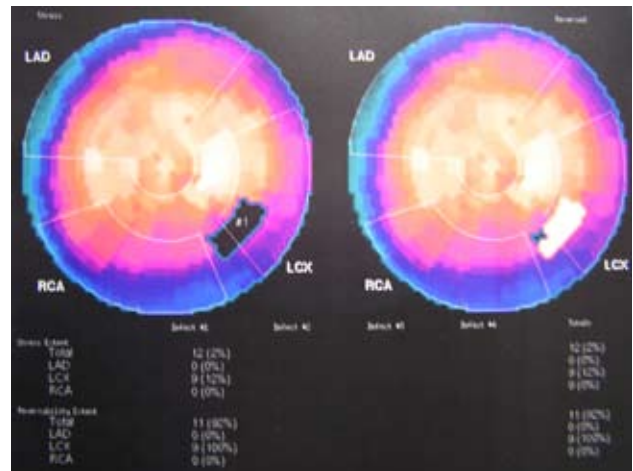
Figure 4. SPECT scan results from preoperative to postoperative period.



4 month SPECT scan

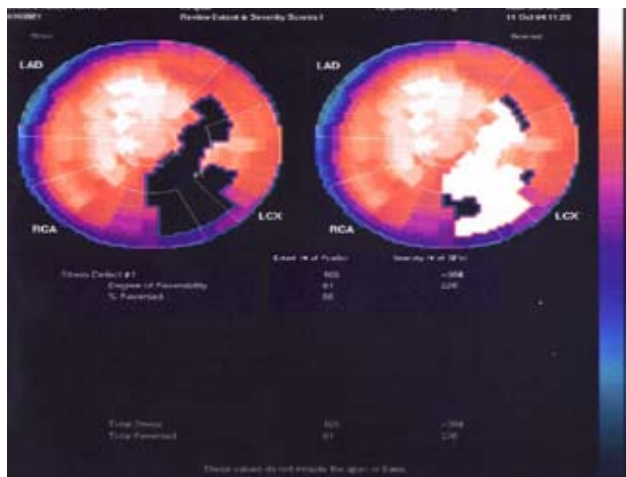


Preoperative SPECT scan



At 12 month SPECT scan

Figure 5. SPECT scan showing improvement in areas of defect (black area) and reversibility (white area)



At 1 month SPECT scan

Discussion

The present report describes the first clinical trial of direct intramyocardial injections using high cell count of autologous bone marrow stem cell with a mean of 2.4×10^8 cells as a sole therapy for patients who have severe ischemic heart disease whom are not suitable for normal revascularization methods. The number of patients are small because of the strict criteria used in patients selection. This is also compounded by the aggressiveness of most interventional cardiologist in treating triple vessel disease with percutaneous intervention and the improvement of surgical techniques in coronary bypass surgery. Nevertheless our results

showed that the intramyocardial injections using high cell count of autologous bone marrow stem cell procedure is relatively safe. There was no death or cerebrovascular events during the implantation or during the follow up period. All the mononuclear cells from the bone marrow aspirate were used as a whole, rather than subpopulation as each fraction of the bone marrow cells might contribute to the regeneration of ischemic myocardium. There were no recorded arrhythmias with the 24 hour holter during the follow-up period. There was significant improvement in symptoms of angina and effort tolerance as early as 1 month as shown in Figures 1 and 2. Although this highly subjective, this is supported by the transthoracic echocardiography which showed improvement in left ventricular ejection fraction from $50\pm 9\%$ preoperatively to $57\pm 10\%$ at 4 month and complimented with improvement in left ventriculogram ejection fraction from $61\pm 6\%$ preoperatively to $69\pm 17\%$ at 4 months. The analysis of the areas of defect and reversibility demonstrated some very interesting findings (Figures 3, 4 and 5). We had expected the direct trauma caused by the intramyocardial injections and thus predicted a time interval taken for angiogenesis and regeneration to occur, might make the areas of defect and reversibility to increase before any improvement was to be expected. This is clearly shown from the Figures 4 and 5 where the areas of defect and reversibility were increased at 1 month but subsequently decreased during follow-up period. These results demonstrate that the injection of high cell count of autologous bone marrow stem cells may lead to angiogenesis and repair of the ischemic myocardium although the objective measurements do not reached values of statistical significance due to the small number of patients. It also showed that the simple approach of direct intramyocardial injection into areas of interest as determined by the preoperative SPECT scan is feasible.

The evidence that cardiac cells may regenerate and the presence of cardiac stem cells stimulated an exciting journey and opportunities for myocardial repair [12-15]. This lead to the idea that the heart may be a terminally differentiated organ but does not composed

wholly of terminally differentiated cells. Recent clinical trials using autologous bone marrow stem cells in infarcted hearts have shown functional improvements [4-11]. Other clinical trials with the use of skeletal myoblast transplantation were equally encouraging [16,17]. The postmortem findings in some of these patients proved that engraftment and transdifferentiation may have occurred in both methods [18,19] However both methods of cellular therapy trials were done concomitantly with coronary artery bypass graft surgery or following angioplasties. Our study records two new approaches that differ from previous trials. Primarily we used a high cell count of autologous bone marrow stem cells, and secondly we performed this procedure as a sole therapeutic modality. Our preliminary findings showed that it is relatively safe and very encouraging early results were obtained. It is however must be reiterated that this therapy is not intended to be a first- or second-line therapy. This study aimed to find an alternative therapy that is reserved for those who are symptomatic despite on maximum medical therapy and are not suitable for any means of revascularisation methods. Therefore larger prospective randomized trials are required before such novel therapies could routinely be implemented. Hopefully we would know then which cells to use, how much to use and the best method of delivery for such cells .

Acknowledgement

We thank Faizal Ramli for statistical help.

References

1. Tateishi-Yuyama E, Matsubara H, Murohara T, Ikeda U, Shintani S, Masaki H, Amano K, Kishimoto Y, Yoshimoto K, Akashi H, Shimada K, Iwasaka T, Imaizumi T. 2002. Therapeutic angiogenesis for patients with limb ischaemia by autologous transplantation of bone-marrow cells: a pilot study and a randomized controlled trial. *Lancet* 360: 427-35.
2. Orlic D, Kajstura J, Chimenti S, Jakoniuk I, Anderson SM, Li B, Pickel J, Mckay R, Nadal-Ginard B, Bodine DM,

- Leri A, Anversa P. 2001. Bone marrow cells regenerate infarcted myocardium. *Nature* 410(6829): 701-705.
3. Kamihata H, Matsubara H, Nishiue T, Fujiyama S, Tsutsumi Y, Ozono R, Masaki H, Mori Y, Iba O, Tateishi E, Kosaki A, Shintani S, Murohara T, Imaizumi T, Iwasaka T. 2001. Implantation of bone marrow mononuclear cells into ischaemic myocardium enhances collateral perfusion and regional function via side supply of angioblasts, angiogenic ligands, and cytokines. *Circulation* 104:1046-1052.
 4. Strauer BE, Brehm M, Zeus T, Kostering M, Hernandez A, Sorg RV, Kogler G, Wernet P. 2002. Repair of infarcted myocardium by autologous intracoronary mononuclear bone marrow cell transplantation in humans. *Circulation*. 106:1913-1918
 5. Assmus B, Schächinger V, Teupe C, Britten M, Lehmann R, Dobert N, Grunwald F, Aicher A, Urbich C, Martin H, Hoelzer D, Dimmeler S, Zeiher AM. 2002. Transplantation of progenitor cells and regeneration enhancement in acute myocardial infarction (TOPCARE-AMI). *Circulation* 106:3009-3017.
 6. Perin EC, Dohmann HFR, Borojevic R, Silva SA, Sousa ALS, Mesquita CT, Rossi MID, Carvalho AC, Dutra HS, Dohmann HJF, Silva GV, Belem L, Vivacqua R, Rangel FOD, Esporcate R, Geng YJ, Vaughn WK, Assad JAR, Mesquita ET, Willerson JT. 2003. Transendocardial, autologous bone marrow mononuclear cell implantation. *Lancet* 107: 2294-2302.
 7. Stamm C, Westphal B, Kleine H-D, Petzsch M, Kittner C, Klinge H, Nienaber CA, Freund M, Steinhoff G. 2003. Autologous bone-marrow stem-cell transplantation for myocardial regeneration. *Lancet* 361: 45-46.
 8. Fuchs S, Satler LF, Kornowski R, Okuubagzi P, Baffour R, Waksman R, Weissman NJ, Cerqueira M, Leon MB, Epstein SE. 2003. Catheter-based autologous bone marrow myocardial injection in no-option patients with advanced coronary artery disease: a feasibility study. *J Am Coll Cardiol* 41(10):1721-4.
 9. Ozbaran M, Omay SB, Nalbantgil S, Kultursay H, Kumanlioglu K, Nart D, Pektok E. 2004. Autologous peripheral stem cell transplantation in patients with congestive heart failure due to ischaemic heart disease. *Eur J Cardio-thoracic Surg* 25: 342-351.
 10. Perin EC, Dohmann H F.R., Borojevic R, Silva SA, Sousa ALS, Silva GV, Mesquita Ct, Bele'm, Vaughn WK, Rangel FOD, Assad JAR, Carvalho AC, Branco RVC, Rossi MID, Dohmann HJF, Willerson JT. 2004. Improved exercise capacity and ischaemia 6 and 12 months after transendocardial injection of autologous bone marrow mononuclear cells for ischaemic cardiomyopathy. *Circulation* 110 [II]:13-II-218.
 11. Wollert KC, Meyer GP, Lotz J, Ringes-Lichtenberg S, Breidenbach C, Fichtner S, Korte T, Hornig B, Messinger D, Arseniev L, Hertenstein B, Ganser A, Drexler H. 2004. Intracoronary autologous bone-marrow cell transfer after myocardial infarction: the BOOST randomized controlled clinical trial. *Lancet* 364: 141-48.
 12. Asahara T, Masuda H, Takahashi T, Kalka C, Pastore C, Silver M, Kearne, Magner M, Isner JM. 1999. Bone marrow origin of endothelial progenitor cells responsible for postnatal vasculogenesis in physiological and pathological neovascularization. *Circ Res* 85: 221-228.
 13. Beltrami AP, Urbanek K, Kajstura J, Yan S-M, Finato N, Bussani R, Nadal-Ginard B, Silvestri F, Leri A, Beltrami CA, Anversa P. 2001. Evidence that human cardiac myocytes divide after myocardial infarction. *N Engl J Med* 344(23):1750-1757.

14. Beltrami AP, Barlucchi L, Torella D, Baker M, Limana F, Chimenti S, Kasahara H, Rota M, Musso E, Urbanek K, Leri A, Kajstura J, Nadal-Ginard B, Anversa. 2003. Adult cardiac stem cells are multipotent and support myocardial regeneration. *Cell* 114: 763-776.
15. Laugwitz KL, Moretti A, Lam J, Gruber P, Chen Y, Woodard S, Lin L-Z, Cai C-L, Lu MM, Reth M, Platoshyn O, Yuan JXJ, Evans S, Chien KR. 2005. Postnatal *Isl1*⁺ cardioblast enter fully differentiated cardiomyocytes lineages. *Nature* 433: 647-653.
16. Menasché P, Hagegégé AA, Vilquin J-T, Desnos M, Abergel E, Pouzet B, Bel A, Sarateanu S, Scorsin M, Schwartz K, Bruneval P, Benbunan M, Marolleau J-P, Duboc D. 2003. Autologous skeletal myoblast transplantation for severe postinfarction left ventricular dysfunction. *J Am Coll Cardiol* 41:1078-83.
17. Siminiak T, Kalawski R, Fiszer D, Jerzykowska O, Rzezniczak J, Rozwadowska N, Kurpisz M. 2004. Autologous skeletal myoblast transplantation for the treatment of postinfarction myocardial injury: Phase 1 clinical study with 12 months of follow-up. *Am Heart J* 148:531-7.
18. Pagani FD, DerSimonian H, Zawadzka A, Wetzel K, Edge ASB, Jacoby DB, DInsmore JH, Wright S, Aretz TH, Eisen HJ, Aaronson KD. 2003. Autologous skeletal myoblasts transplanted to ischaemia-damaged myocardium in humans. Histological analysis of cell survival and differentiation. *J Am Coll Cardiol* 41:879-88.
19. Dohmann HFR, Perin EC, Takiya CM, Silva GV, Silva SA, Sousa ALS, Mesquita CT, Rossi MD, Pascarelli BMo, Assis IM, Dutra HS, Assad JAR, Castello-Branco RV, Drummond C, Dohmann HJF, Willerson JT, Borojevic R. 2005. Transendocardial autologous bone marrow mononuclear cell injection in ischemic heart failure. *Circulation* 112: 521-526.